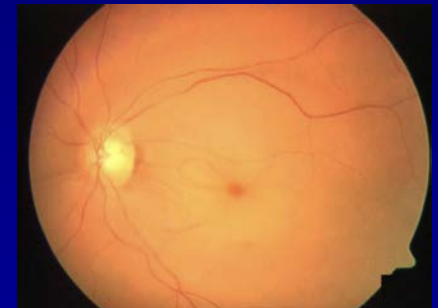
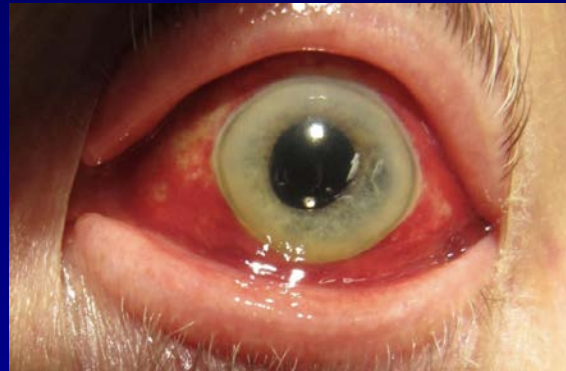
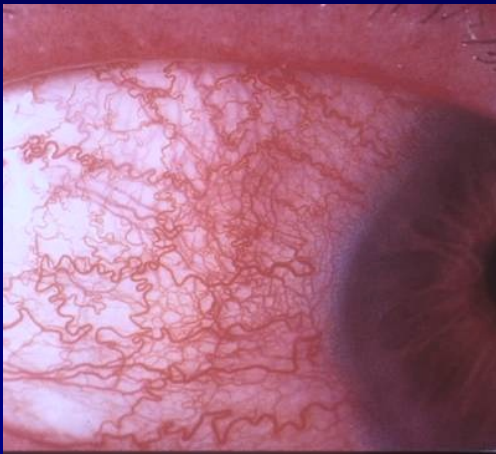

OPHTHALMIC EMERGENCIES IN A&E AND GENERAL PRACTICE



Dr Mya Thida Ohn
FRCS, FRCOphth

Consultant Ophthalmologist, UK
Clinical CME, MMPGA, 23-JAN-2021

Purpose of this presentation

- What is ophthalmic emergency?
- Systematic approach?
- Clinical signs & management plan

What is ophthalmic emergency?

Definition

The Royal College of Ophthalmologists



Ophthalmic Services Guidance

EMERGENCY EYE CARE

An eye condition is an emergency if its occurrence is unpredictable and it requires treatment or admission at short notice to avoid damage to the eye or eyesight.

The College will not attempt to identify every type of case that falls into the emergency category; it is the responsibility of the Consultant under whose care the patient is registered to identify those cases and ensure timely delivery of care. However, examples would be bacterial endophthalmitis, upper bullous retinal

Ocular history

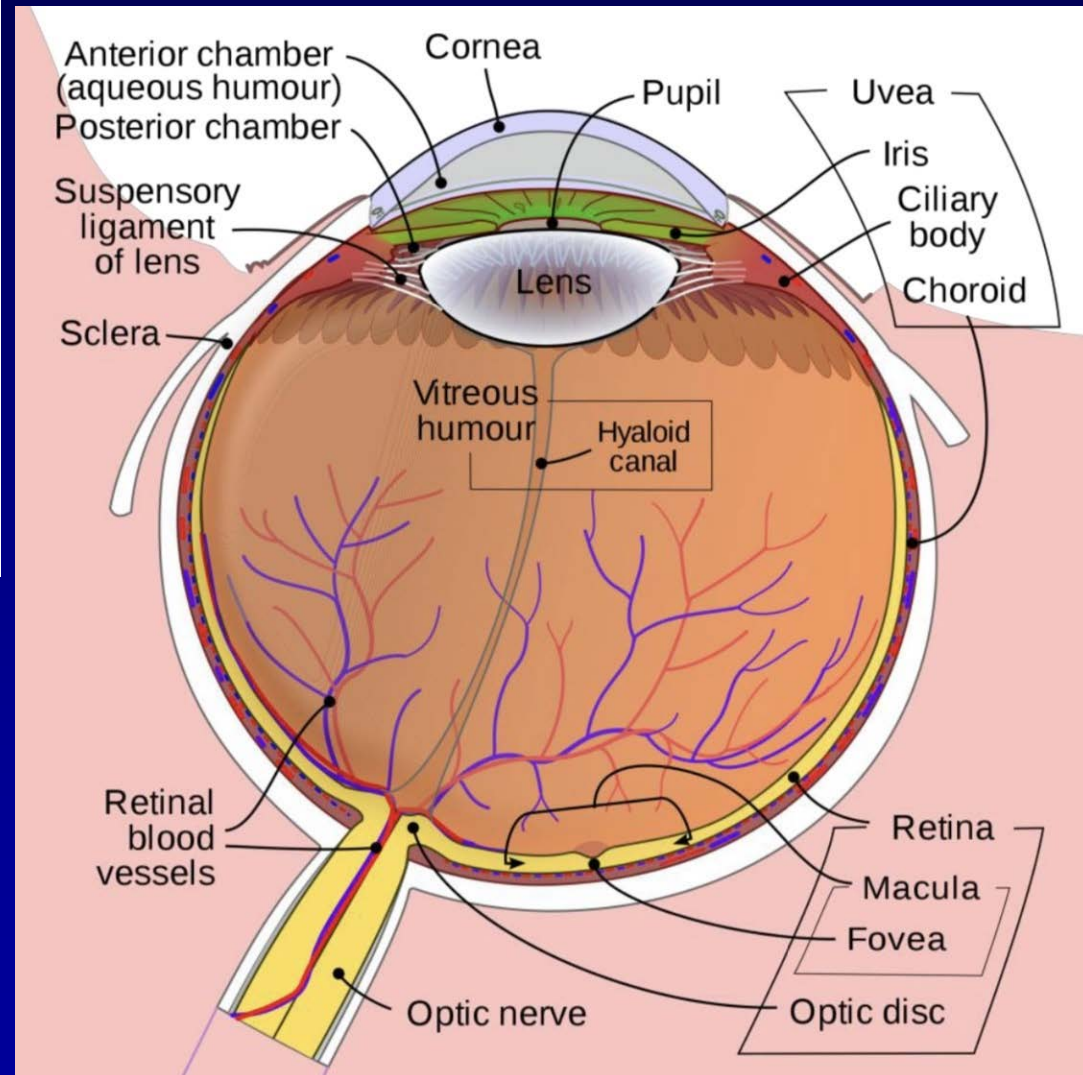
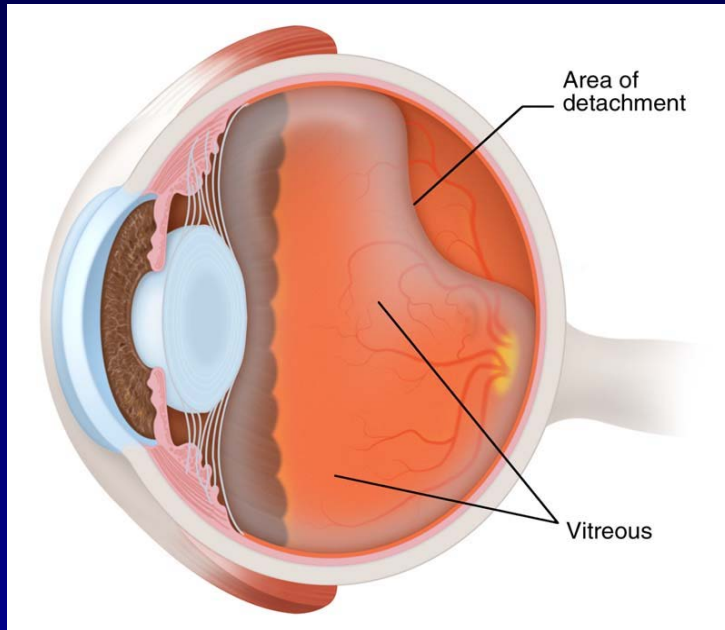
- PC/HPC
- PMHx
- POHx
- Medications
- Allergies
- SH
- FH

Ophthalmic examination

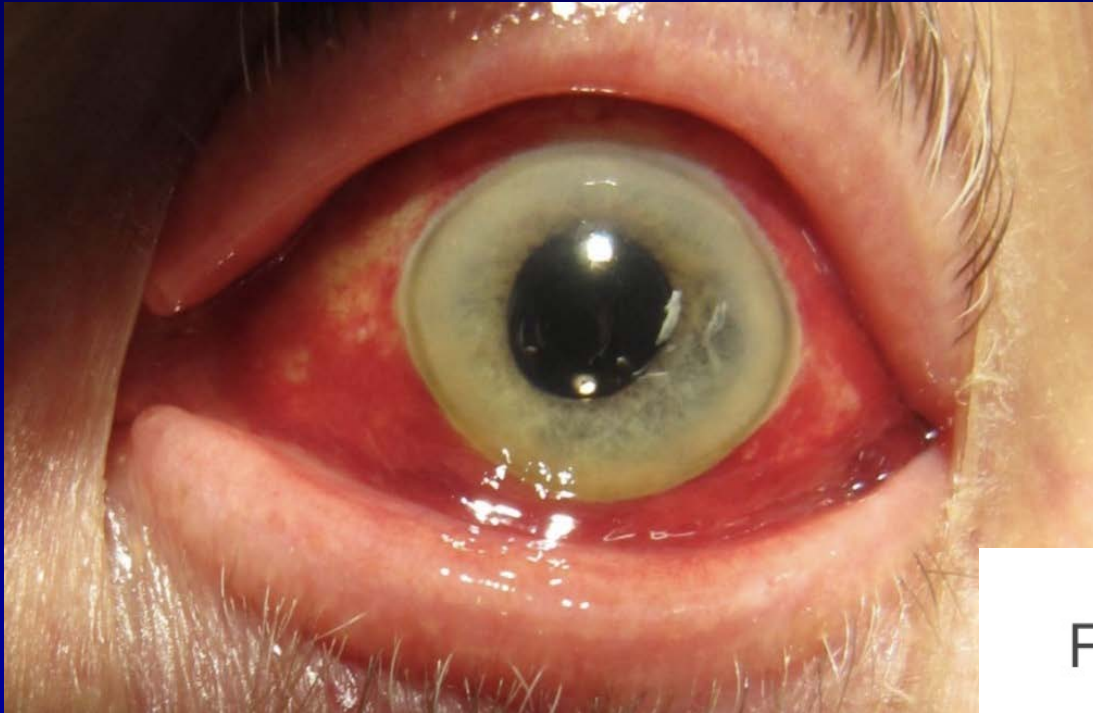
- Visual Acuity (VA)
- Visual fields
- Eye Movements
- Face, lids and orbit
- Conjunctiva and sclera
- Cornea
- Pupils
- Retina (aka Fundus)
- Miscellaneous (colour vision, bionocular vision etc.)



Anatomy of the eye



65 years old woman presented
with sudden onset unilateral red
eye



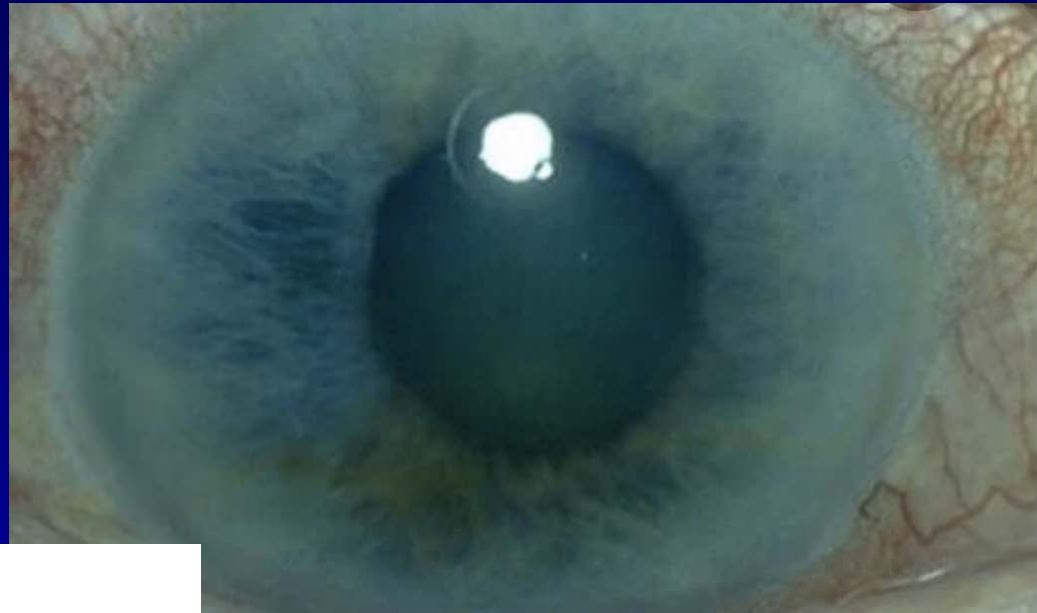
Finding?

Diagnosis?

2 common associations?

42 years old woman presented to A&E with

- Sudden loss of vision in one eye with
- Pain
- Nausea
- Redness

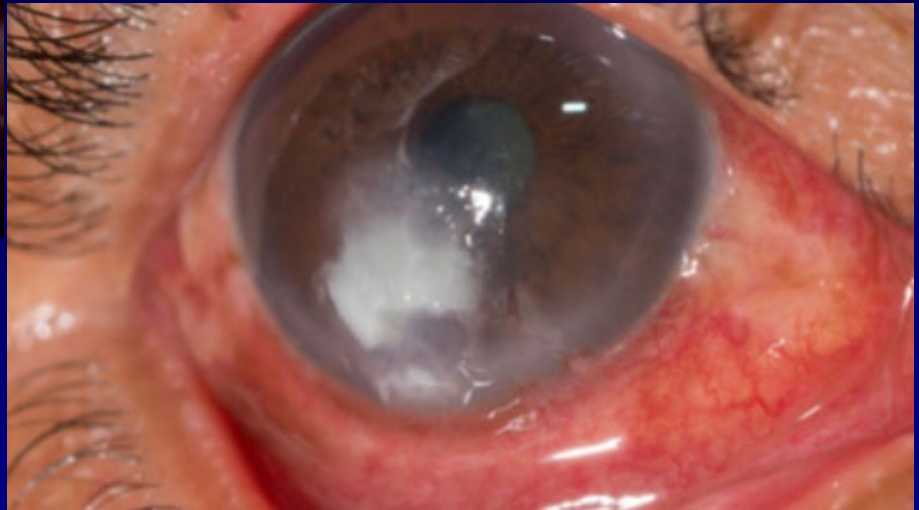
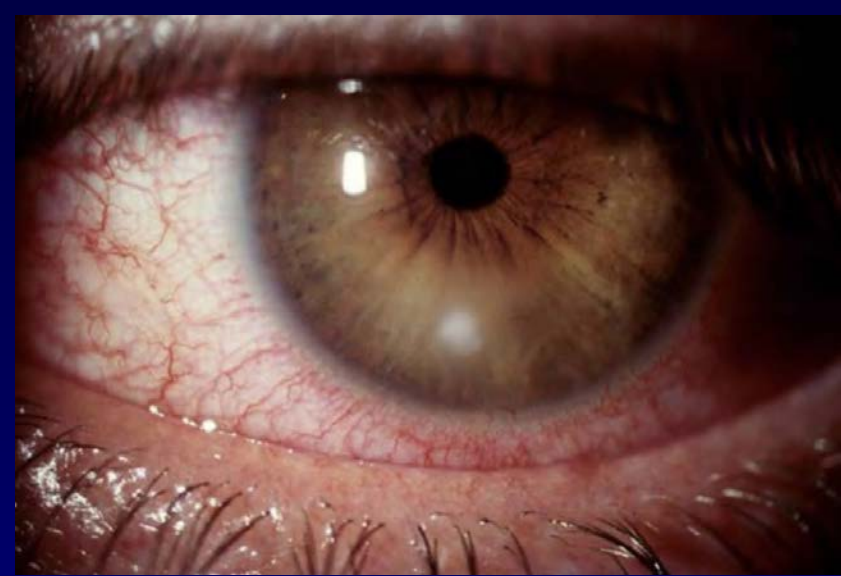
Finding?

Diagnosis?

Does she need urgent referral & why?

Name 2 conditions that can cause this problem.

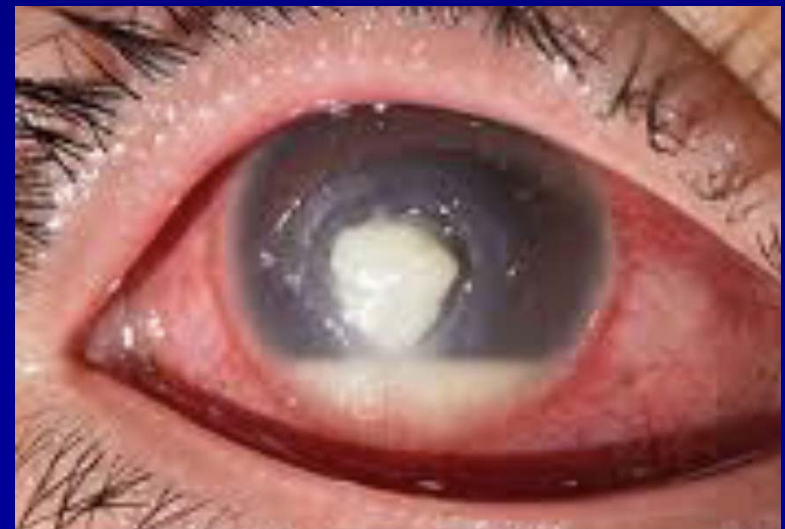

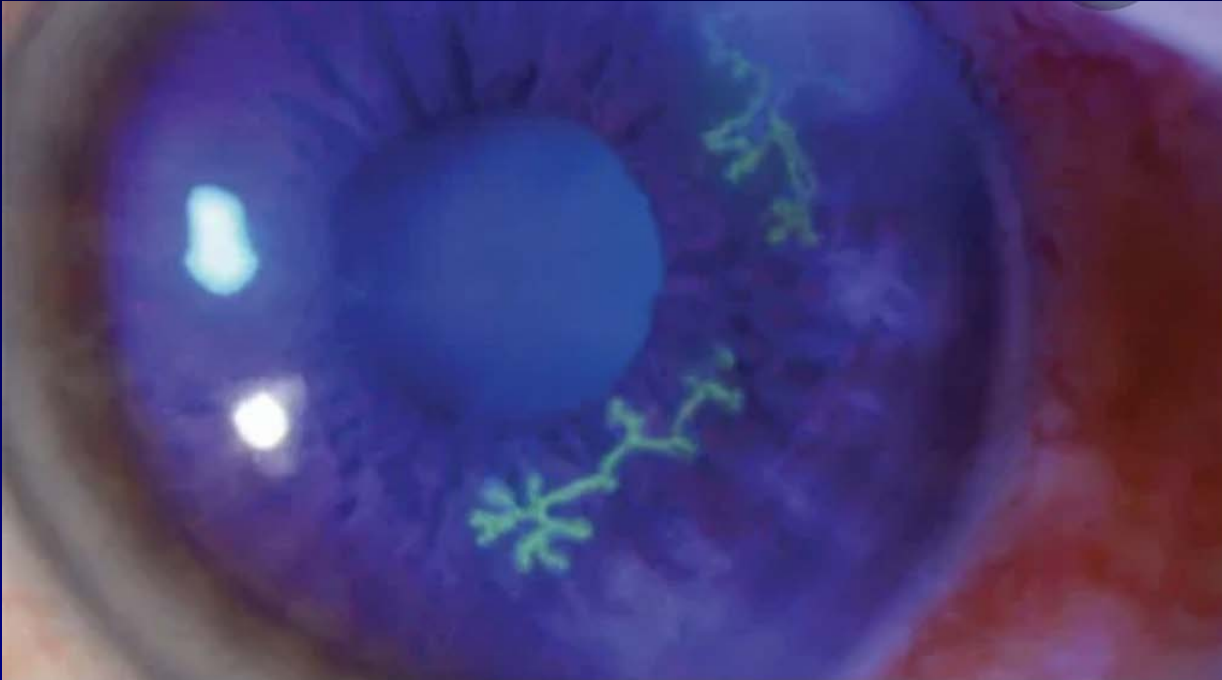Findings?

Diagnosis?

Name 3 risk factors.

Why urgent & what treatment?



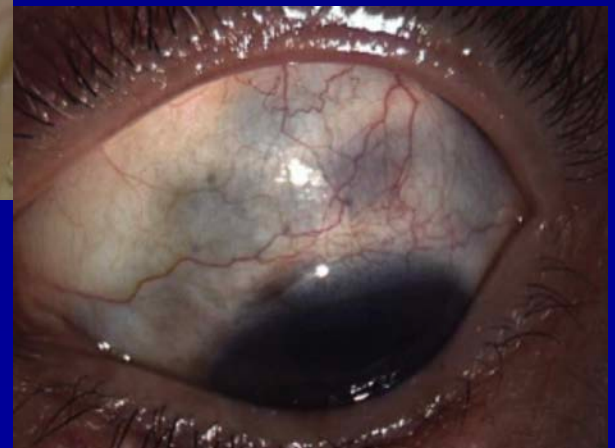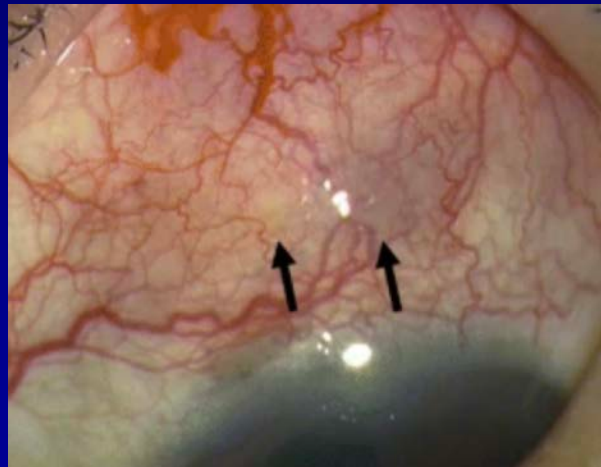
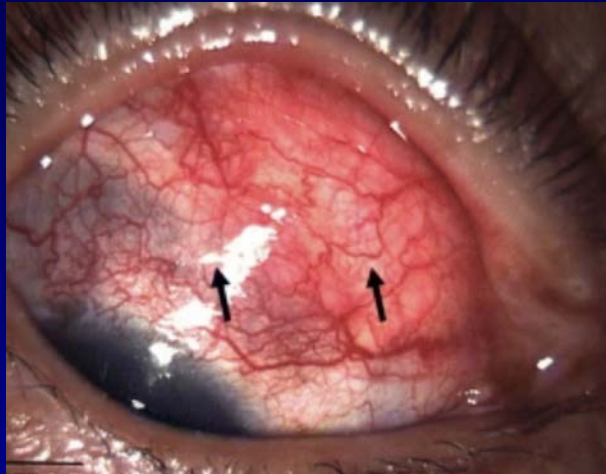


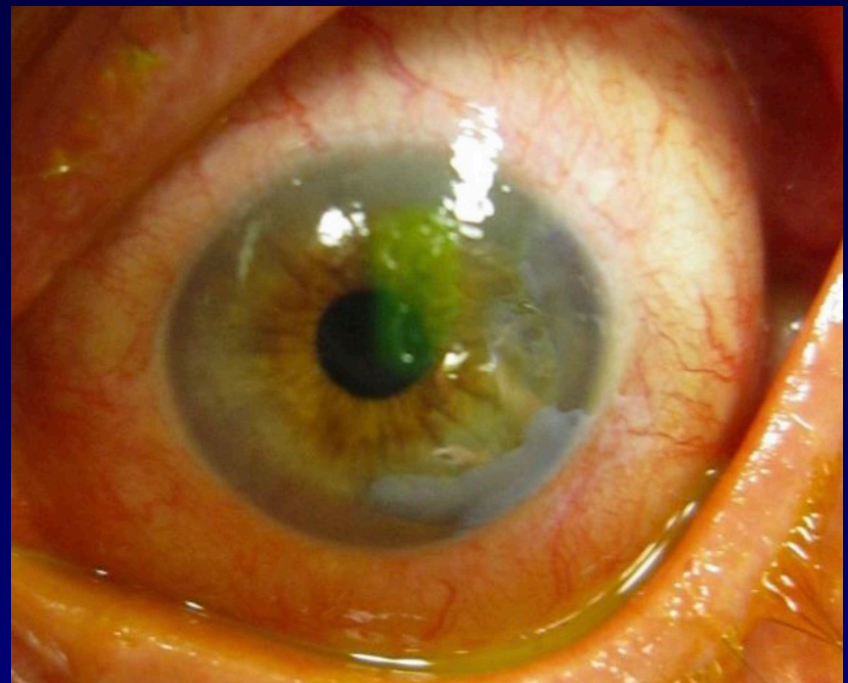
Finding?

Diagnosis?

Would you give steroid & why?

66 years old woman with painful blurred vision
Severe pain that could wake her up
History of rheumatoid arthritis





27 years old man
with unilateral
painful red eye

Findings?

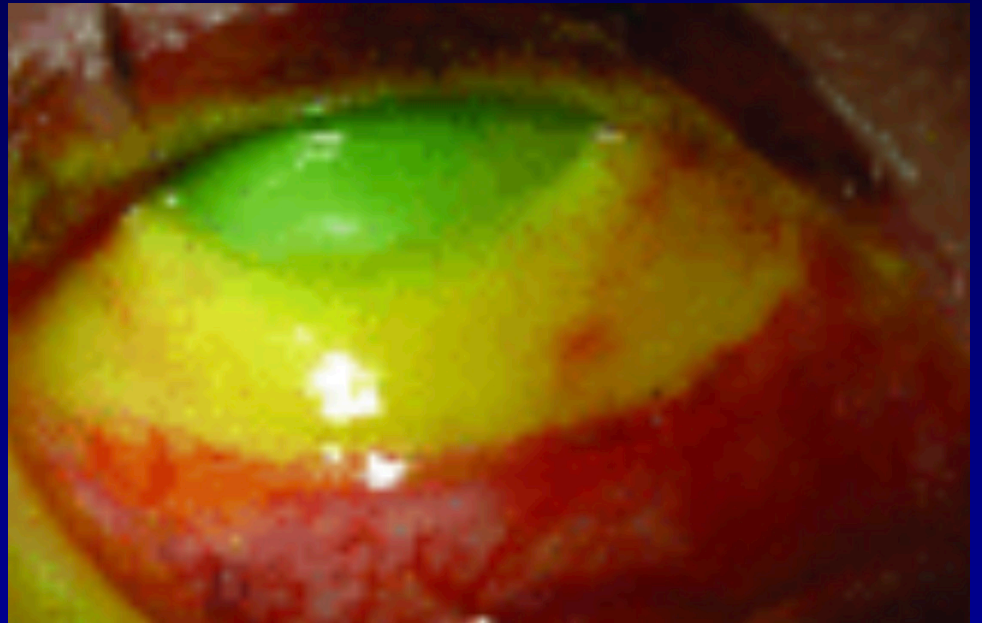
What do you want to know in his history?

What would you avoid when examining this patient?

How urgent it is?

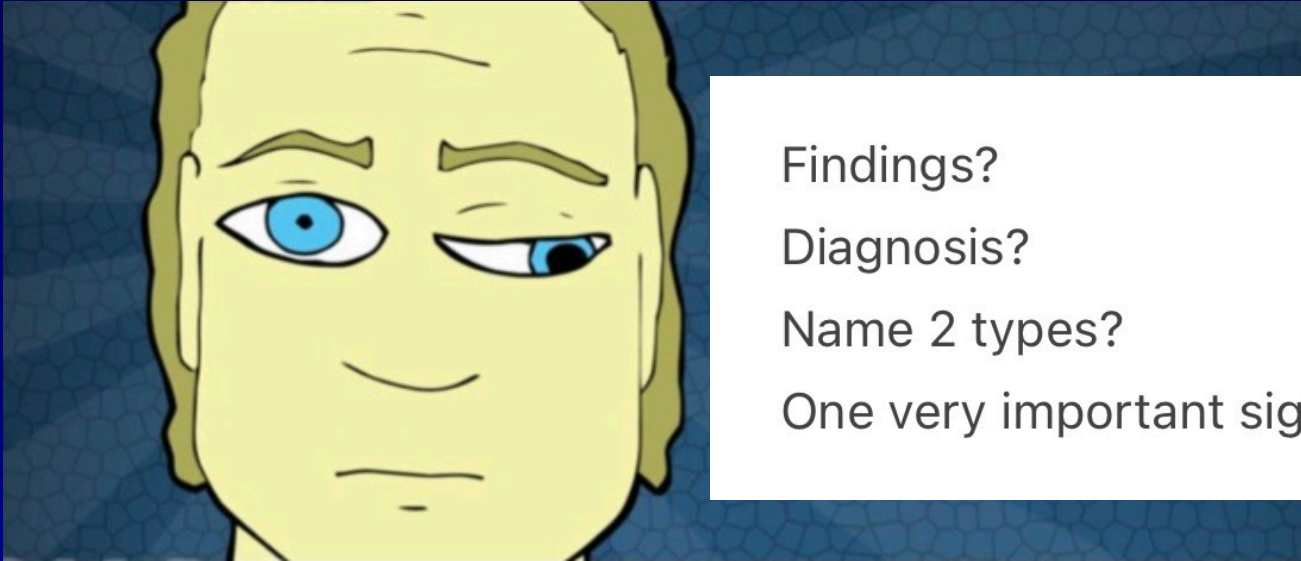
52 years old woman with unilateral painful red eye

- Any history?
- Urgent treatment?



Most urgent treatment you would like to do?

42 years old man unilateral ptosis with diplopia



Findings?

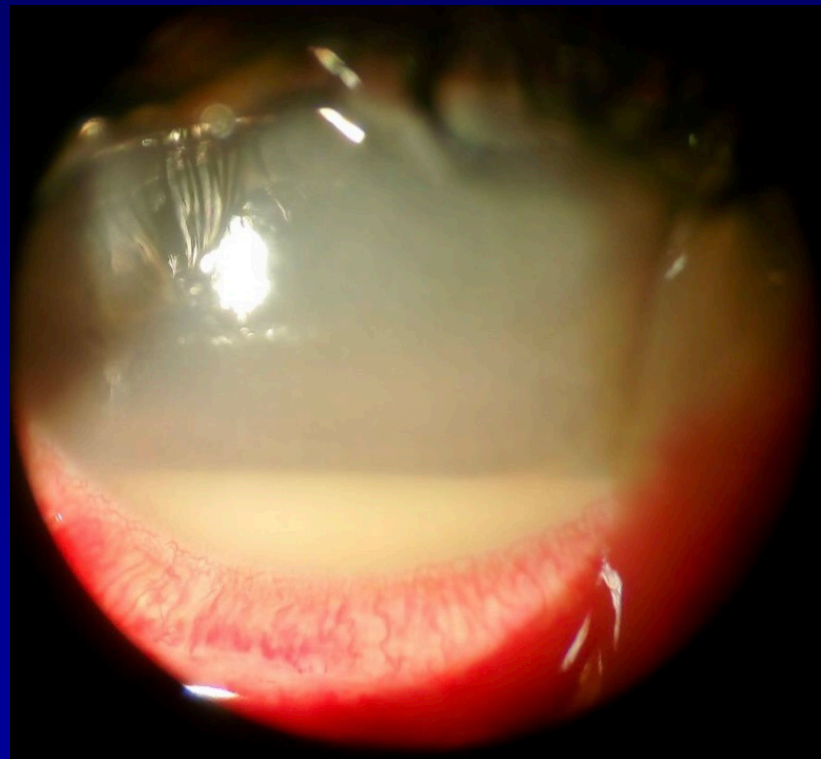Diagnosis?

Name 2 types?

One very important sign to check & why?

85 years old man pain, redness & blurred vision
History of cataract surgery 7 days ago.
Diabetic with poor control

Findings?
Diagnosis?
Name 3 causes
How urgent?
Management plan?

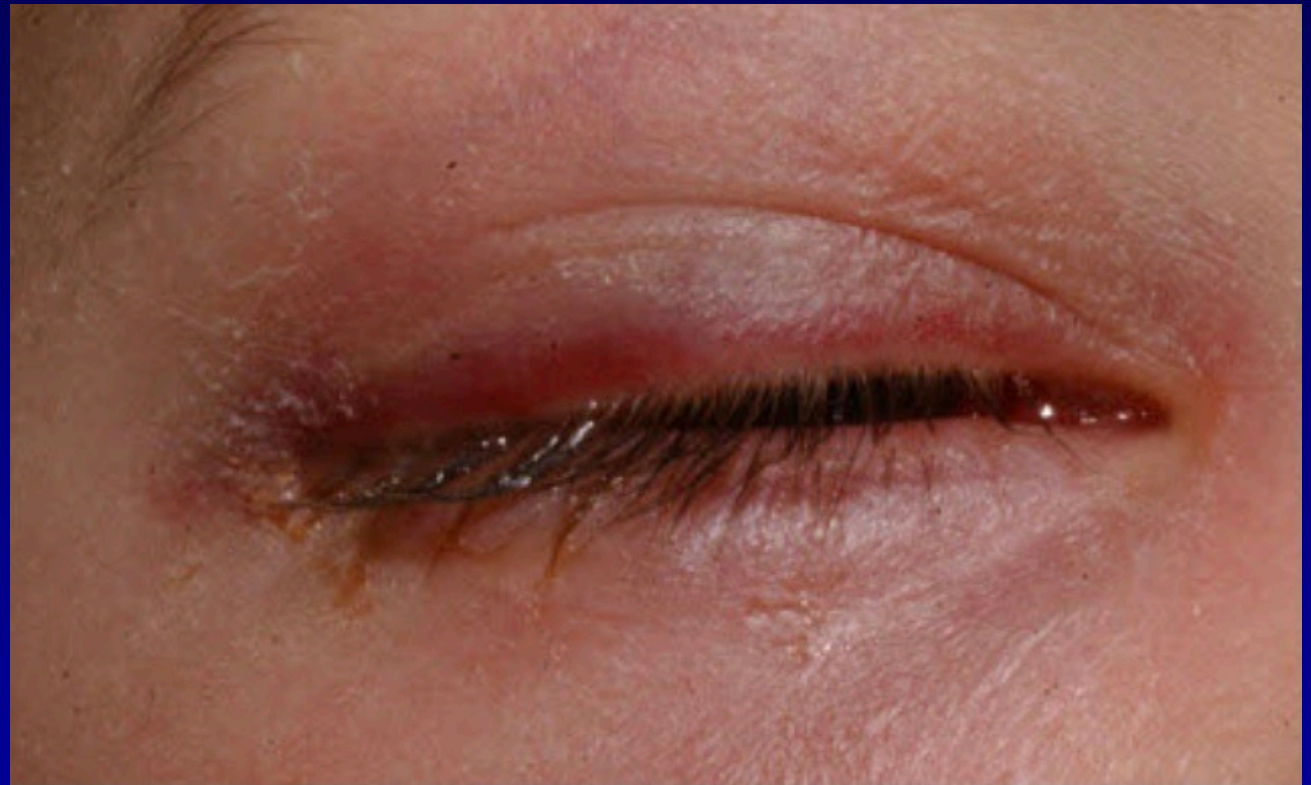

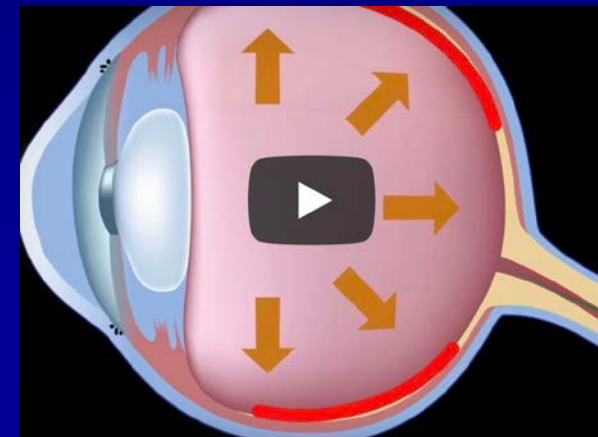
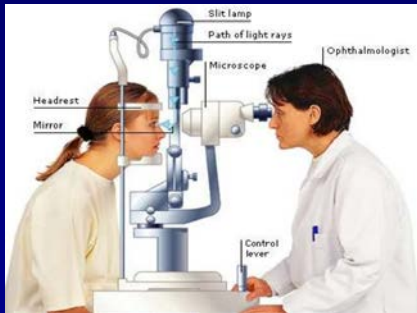
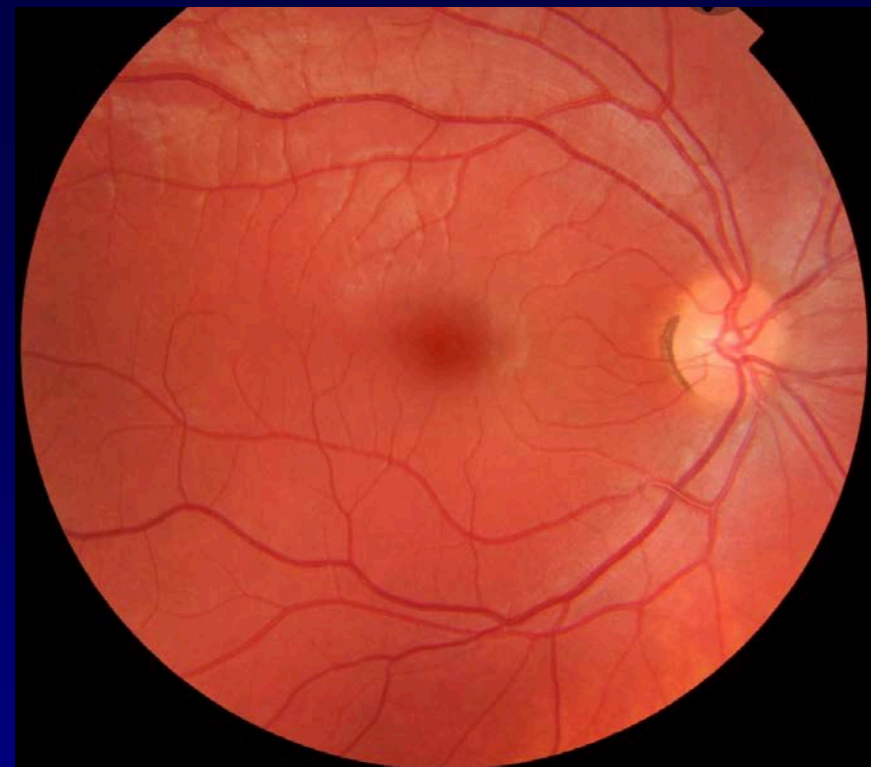
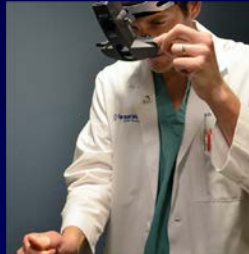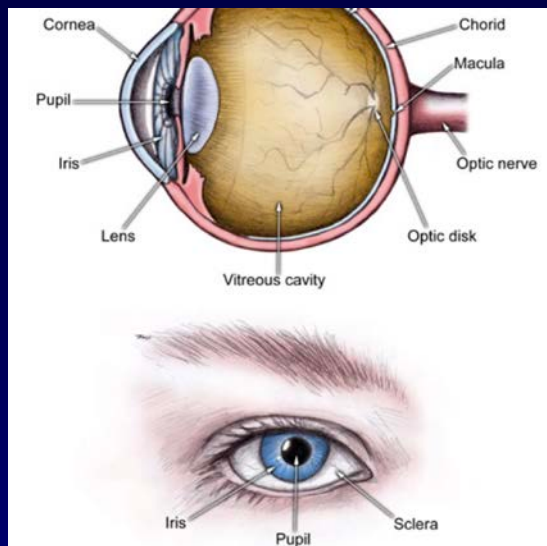
7 years old girl with fever, fatigue, unilateral eye pain and reduce in vision

Name 3 important signs.

What is your diagnosis? |

How would you manage?



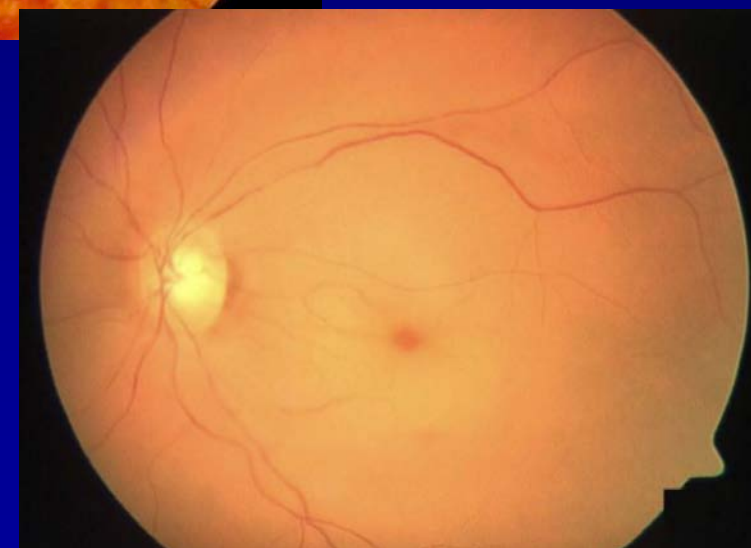
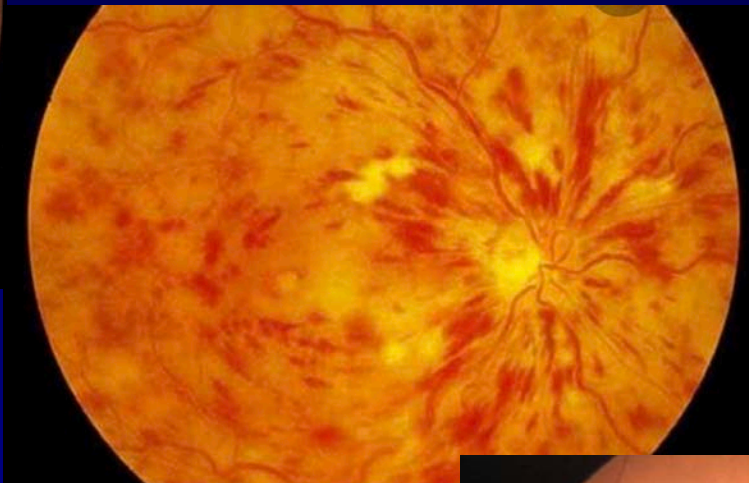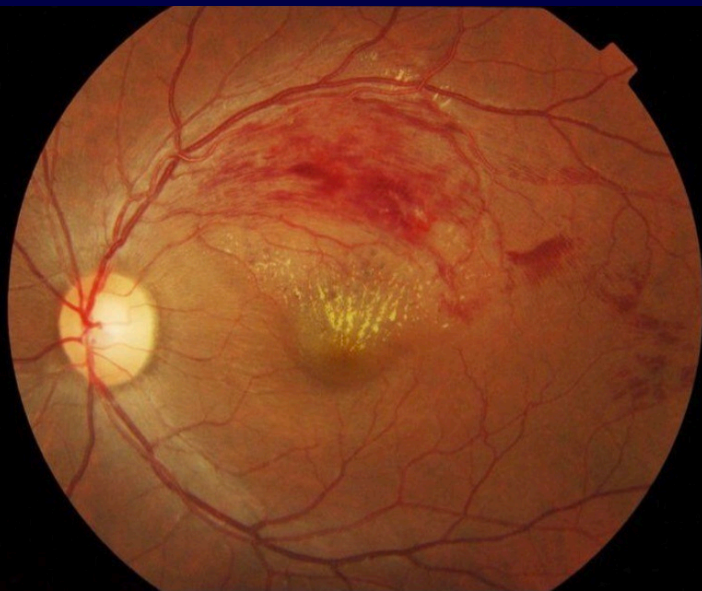


Let's look at the fundus

Name 4 structures that you will check

Which eye in the photo? Right or left?

What instrument do you use?



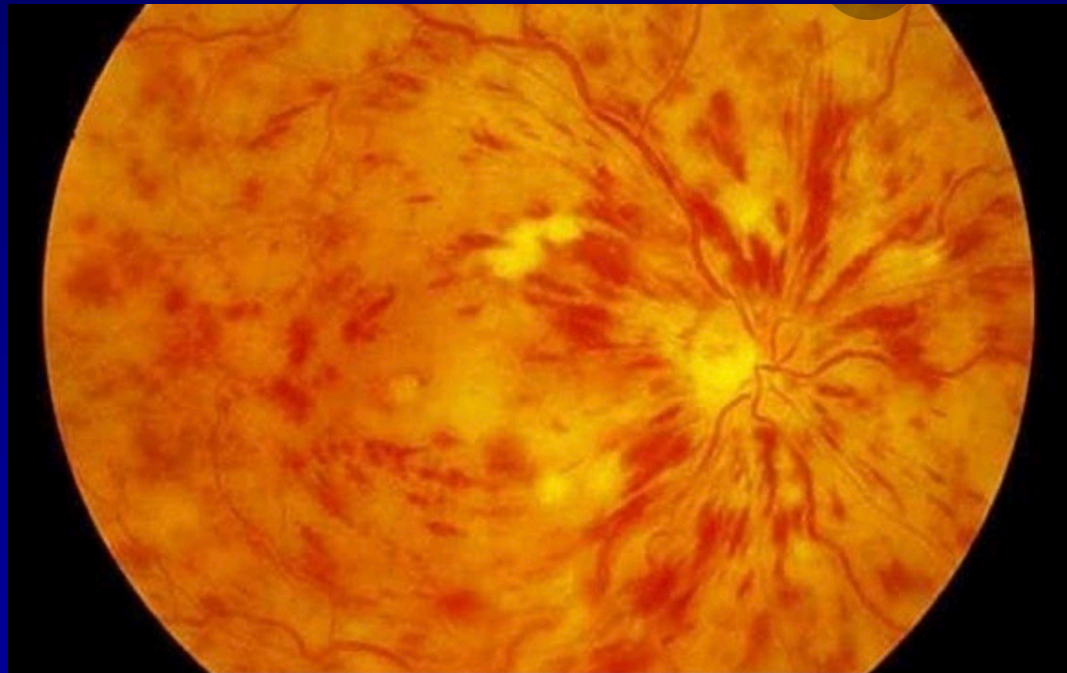Unilateral sudden reduce in vision
Pupil reaction can be abnormal
Other anterior segment findings are normal

58 years old, unilateral blurred vision, sudden onset

Findings?

Diagnosis?

Name 3 risk factors



68 years old unilateral sudden loss of vision

Presented to casualty

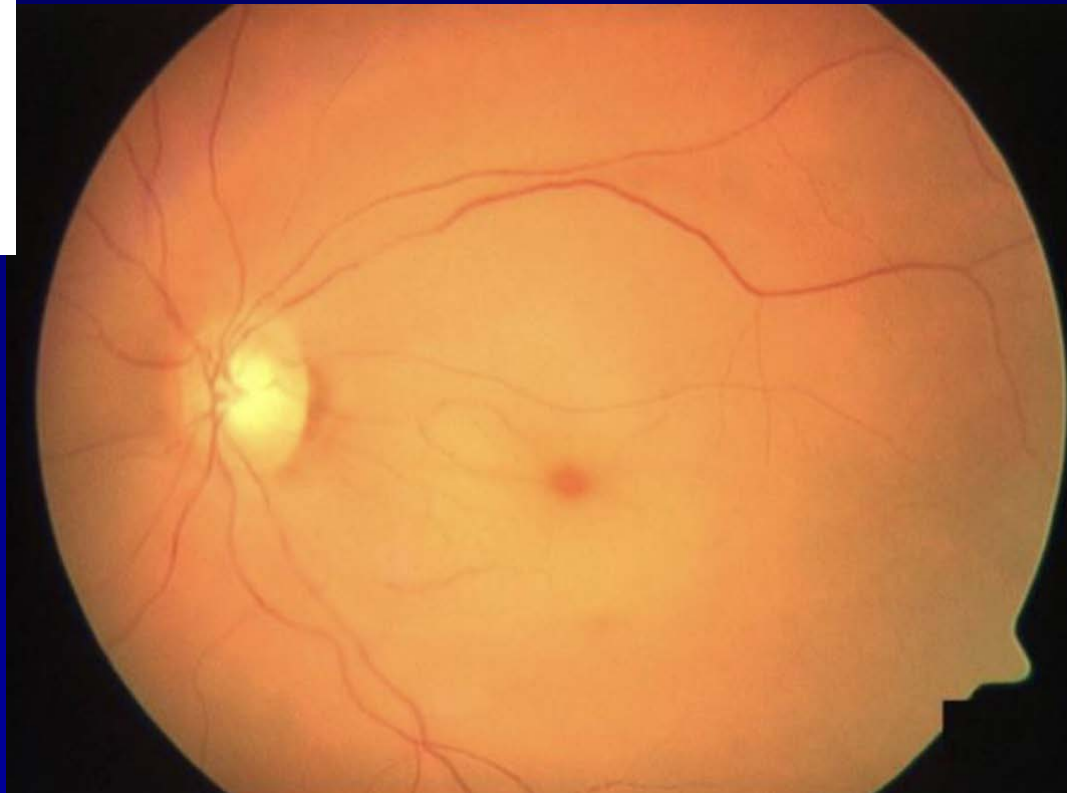
What is your diagnosis and what would you do next?

How would you manage?

Name 2 likely causes.

What are the risks you would worry about?

Findings?



80 years male with unilateral sudden loss of vision

- None - no amblyopia / trauma / surgery

Past medical history

- Hypertension
- Arthritis
- Hip replacement

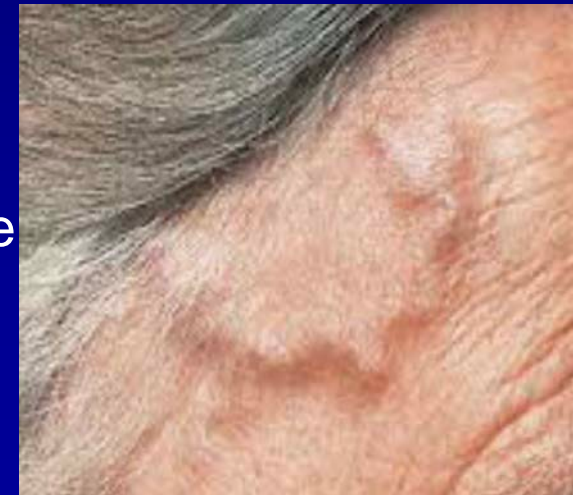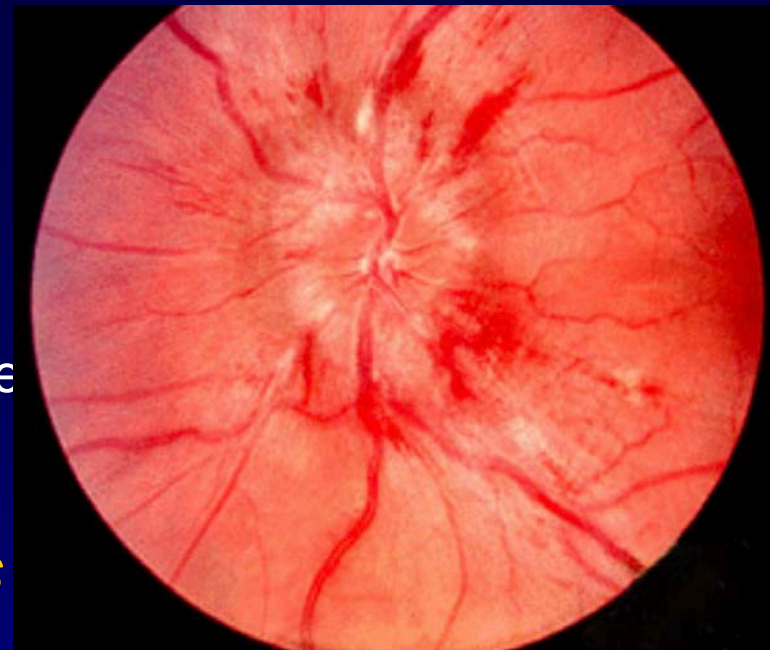
Allergies

- None known

Social

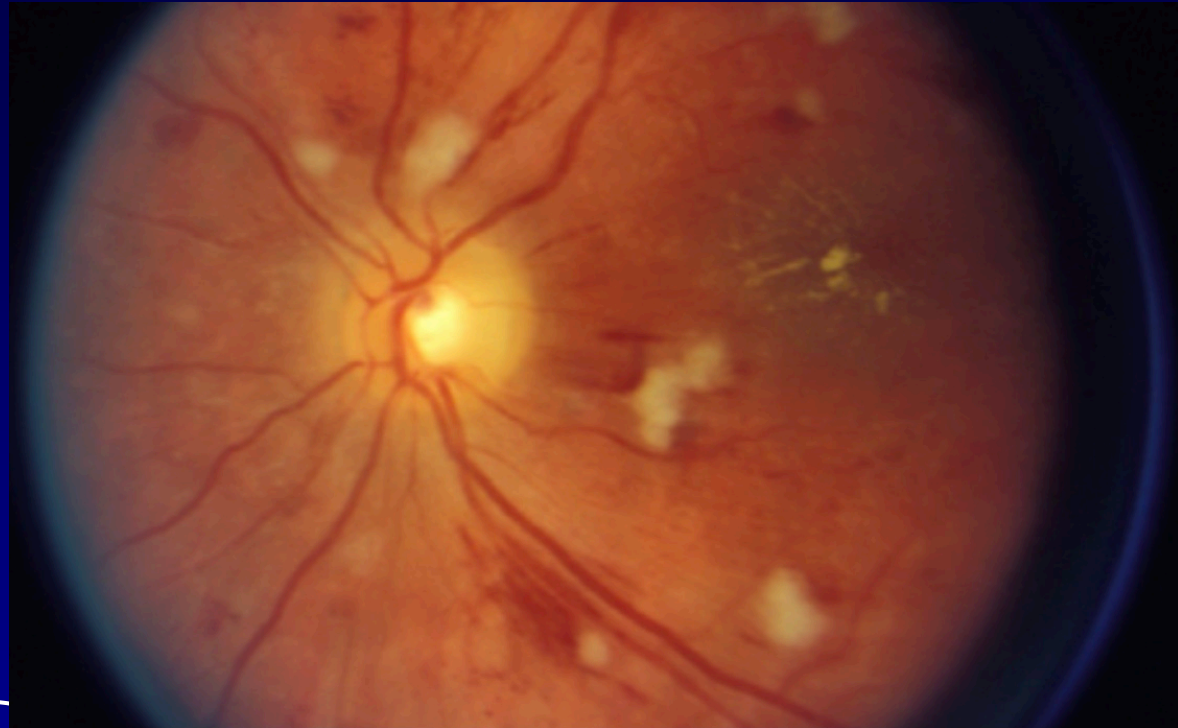- Lives alone

Name 3 symptoms that you will ask the patient?
What urgent investigations would you arrange?
What treatment will you start?
Whom do you want to speak to?
What could be the consequence if it is not treated urgently?



57 years old man who is asymptomatic

Examination



Initial thoughts?

Name 3 findings

Diagnosis?

What would you check in the clinic?

25 years old obese
woman with
Transient blurred vision
Bilateral

Diagnosis?

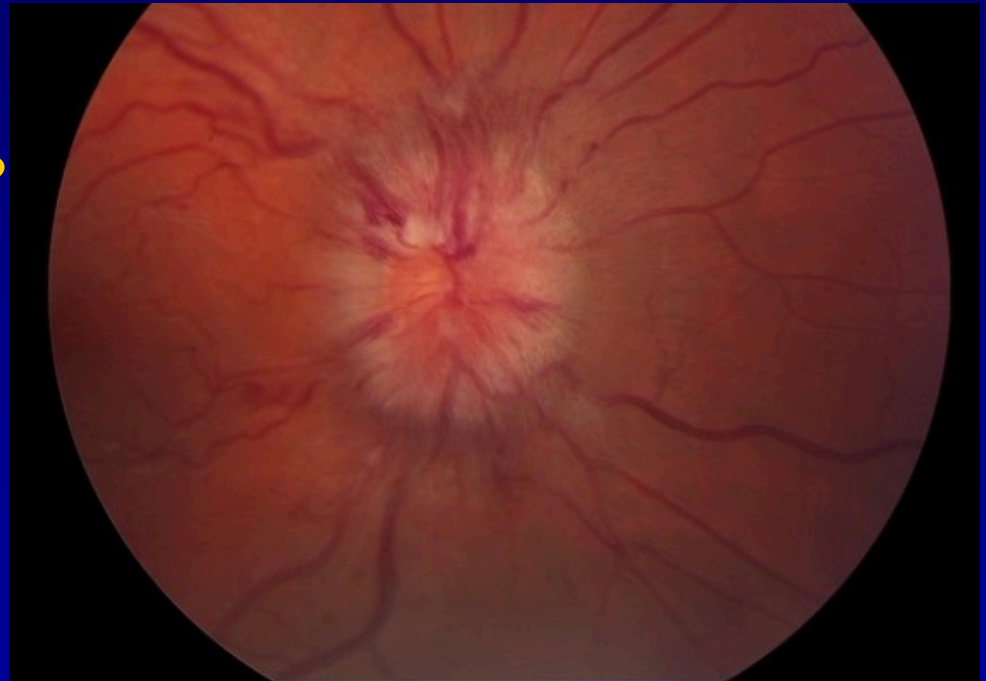What would you do next?

Finding?

Diagnosis?

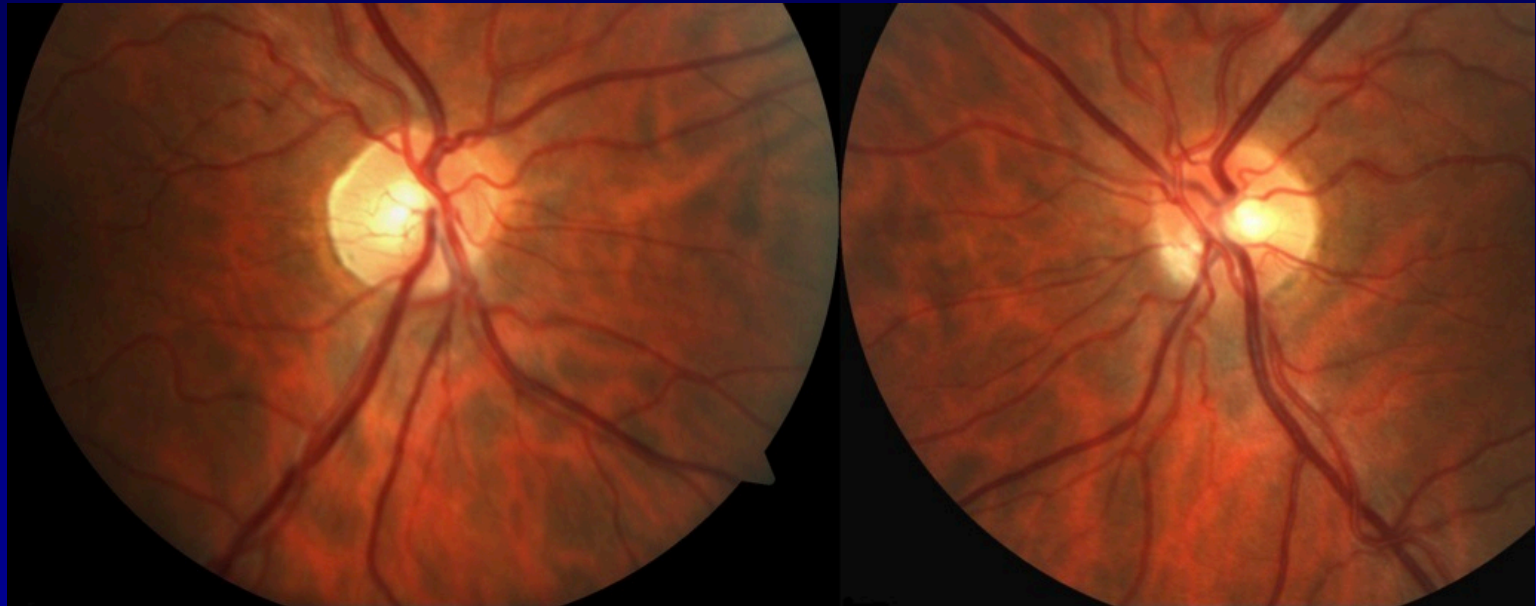
Name 2 conditions

What would you do next?



29 years old man with unilateral visual loss

Pain on eye movement



Diagnosis?

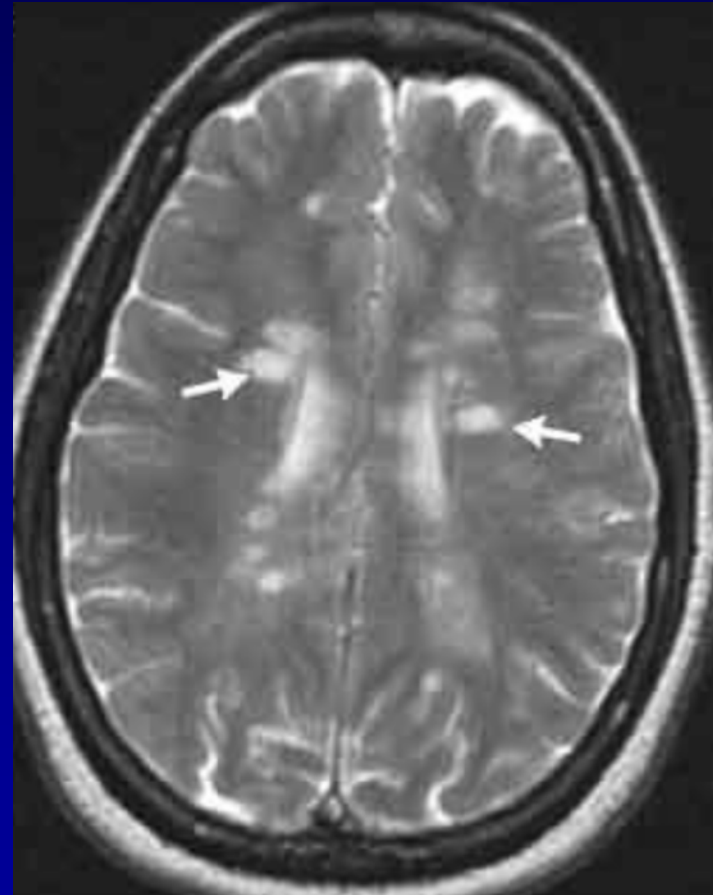
Finding?

What investigation?

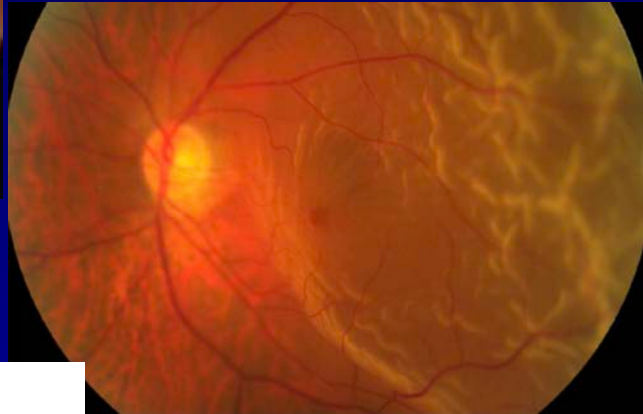
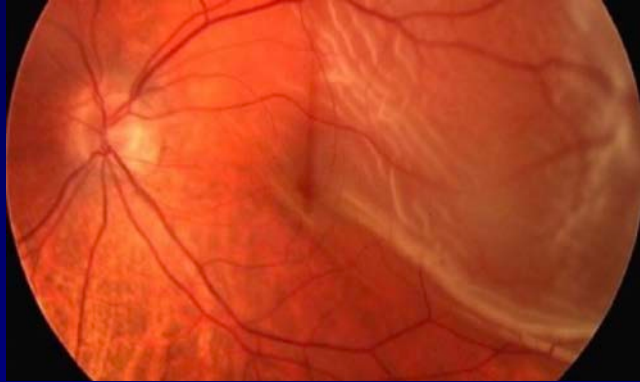
Brain scan of the patient

Finding?

Diagnosis?



40 years old lady with dark shadow in one eye,
then loss of vision

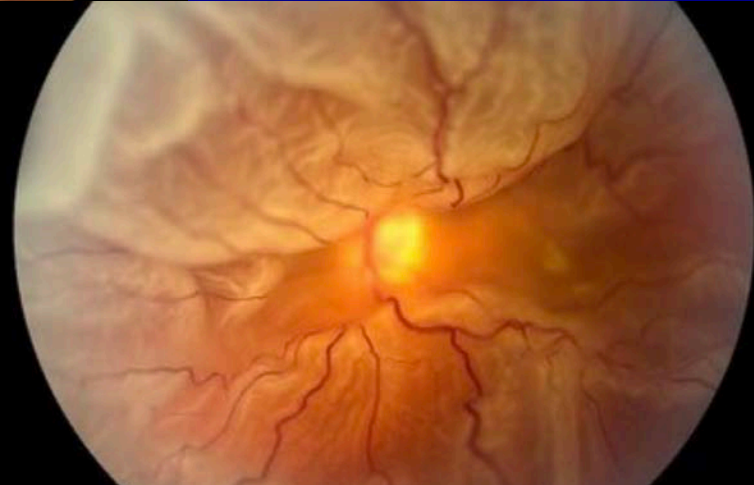

Finding?

Diagnosis?

Any idea on treatment?

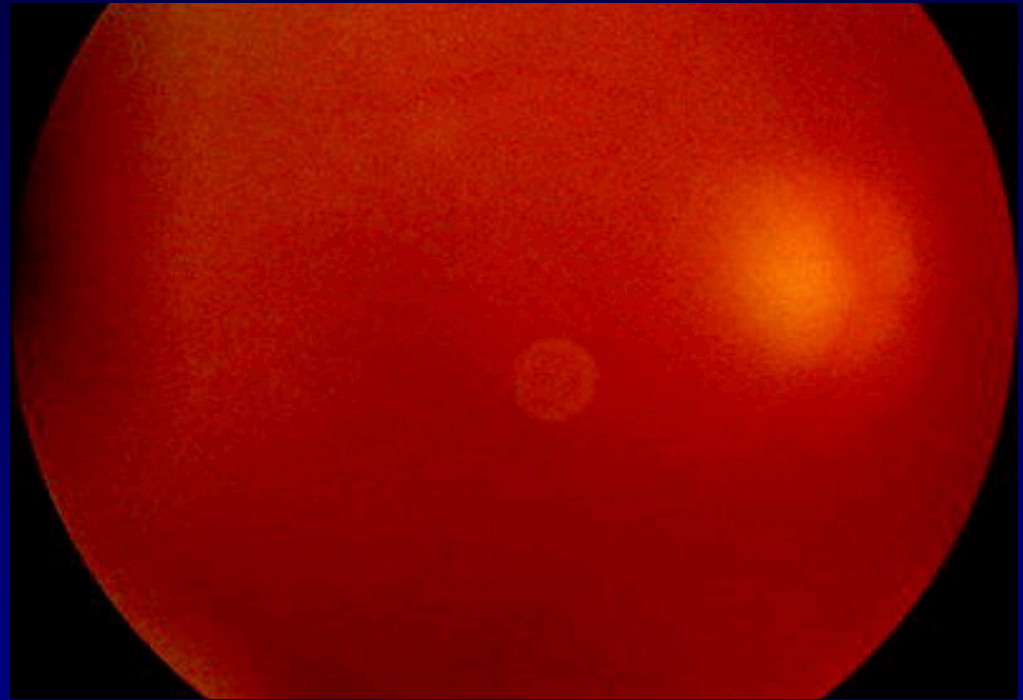
How urgent & why?



50 years old

Symptoms?

- Unilateral sudden loss of vision



Type 1 diabetic since 16 years of age.

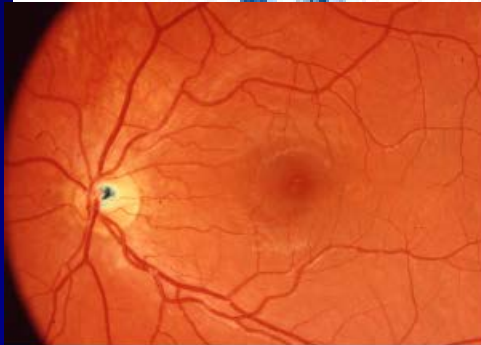Diagnosis?

What are the stages?

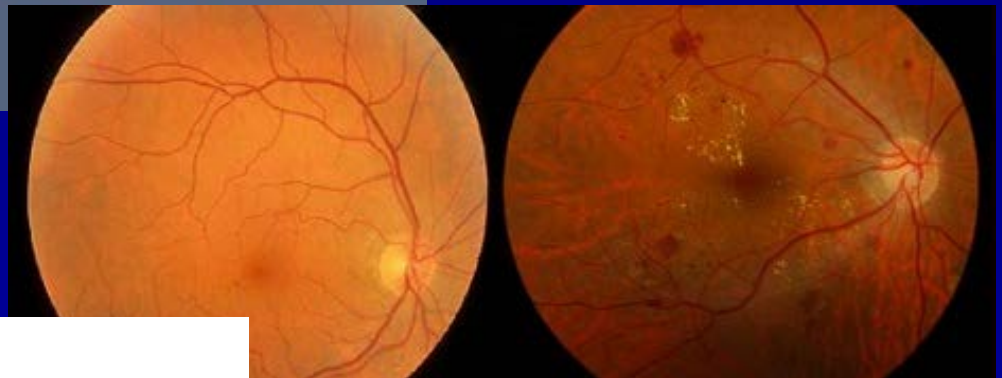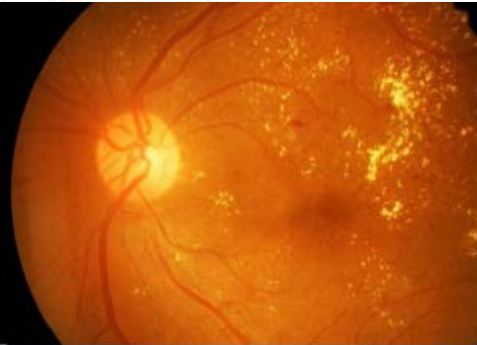Name 3 conditions that can cause this problem.
Why it is urgent?

Diabetic retinopathy

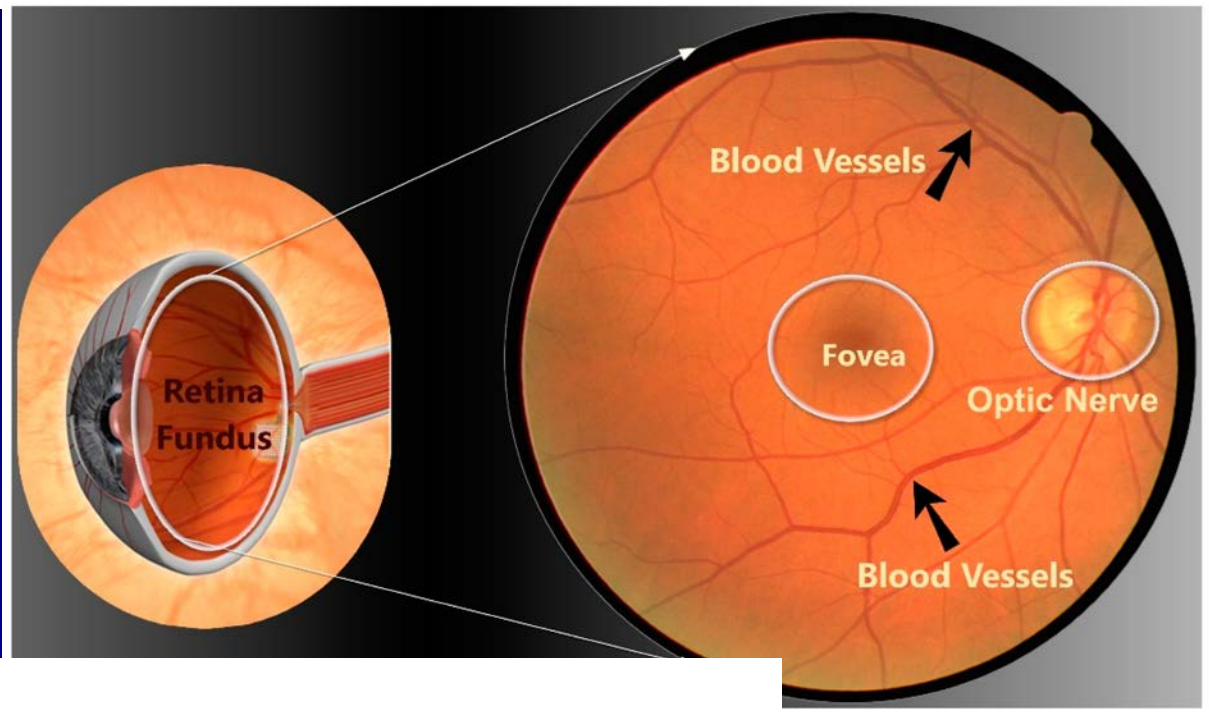
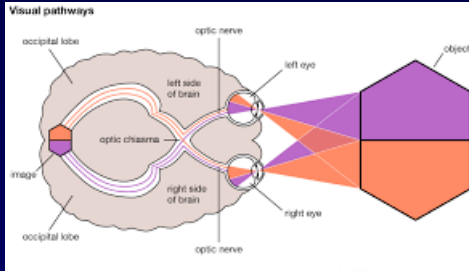
Diabetic retinopathy (DR) is the primary cause of vision loss in adults aged 20–74 years^{1–3}



Normal

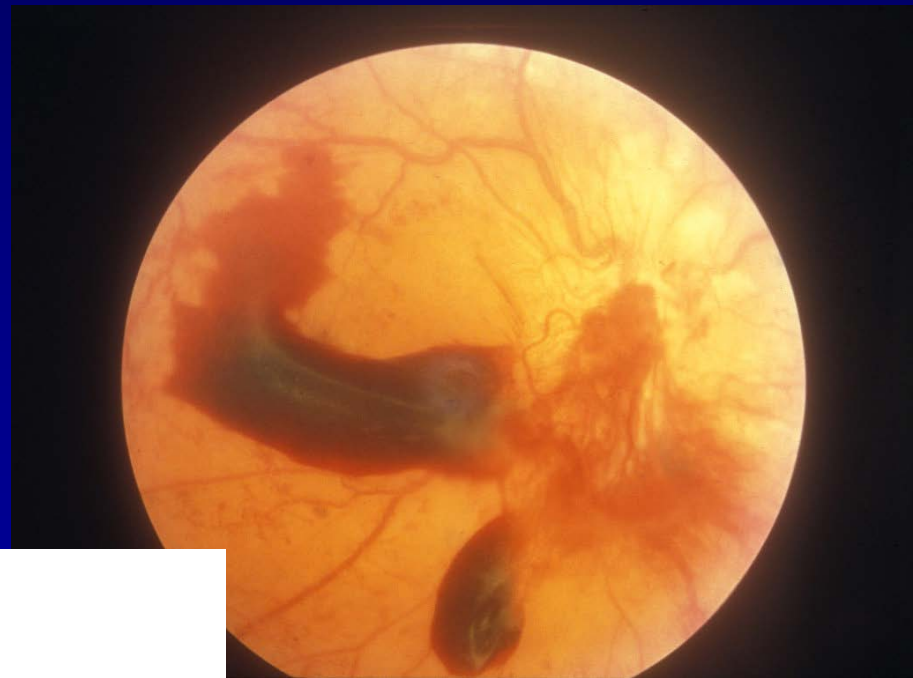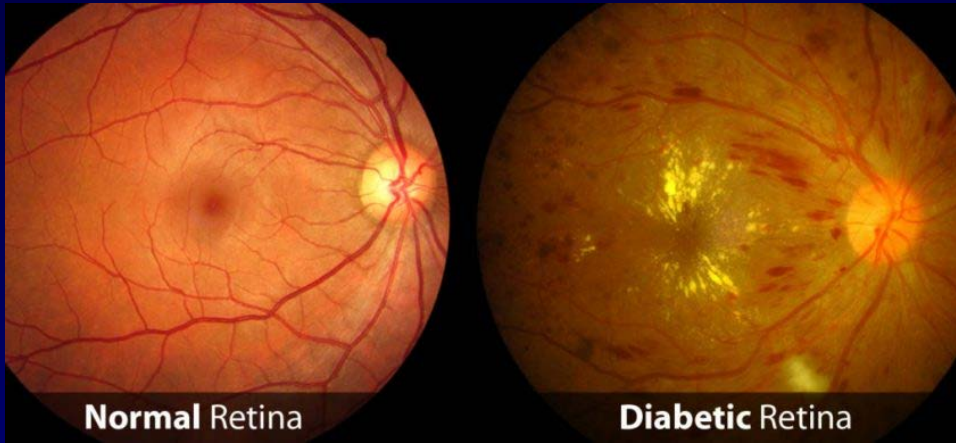


Name 2 pathology that can cause reduce in vision.



Name 4 diabetic related ocular pathology

Name of study BP, BM control in diabetic patients



Findings?

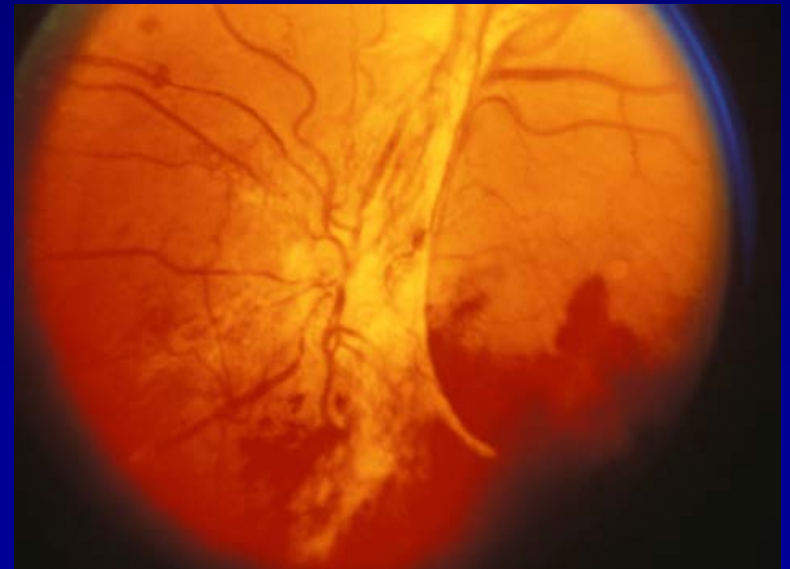
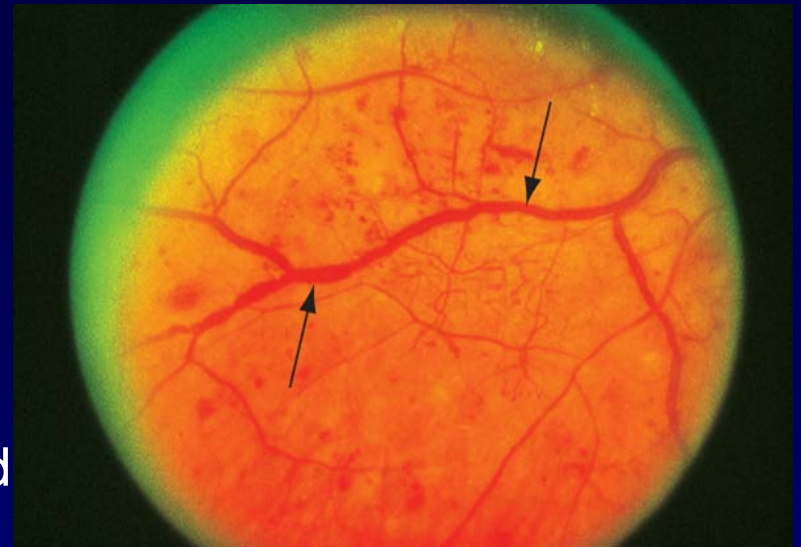
Management plan?

Any treatment to the eyes that you have known?

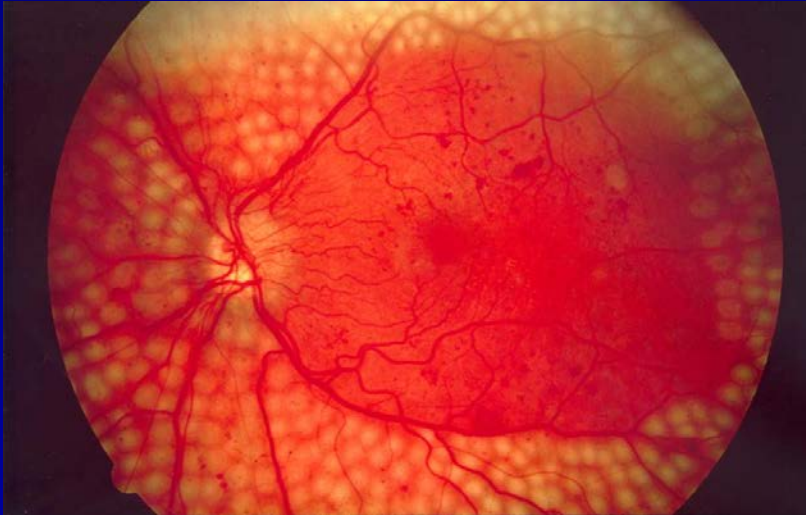
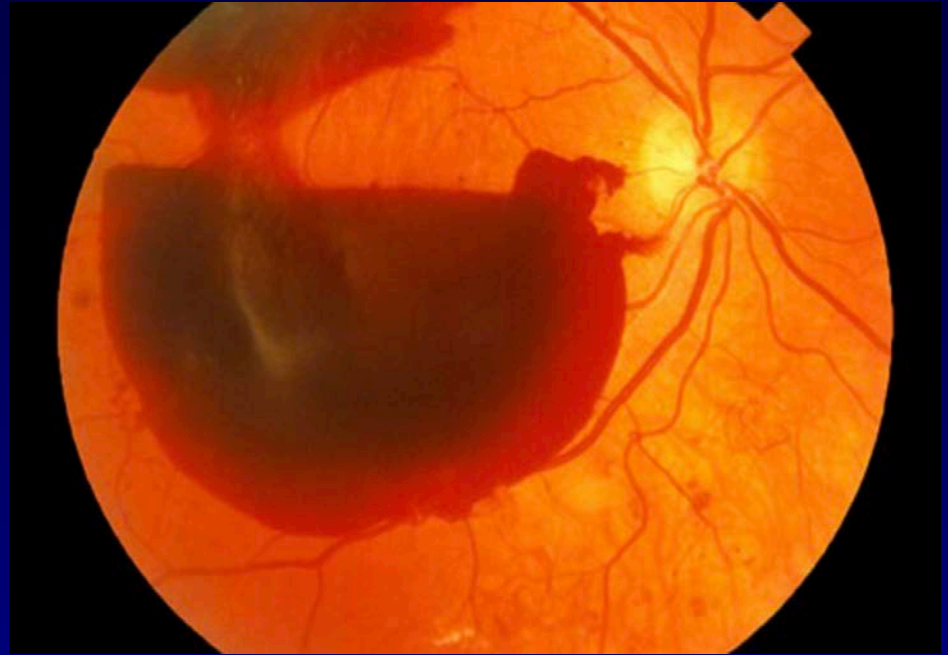
Diabetic retinopathy

PDR

- Diabetes
- Estimated 246 million people worldwide
- 552 million by 2030.
- PDR
- After 15 years,
- 90% of type 1 and 60% of type 2
- Develop retinopathy
- Type 2 – 20% retinopathy at Dx




PDR



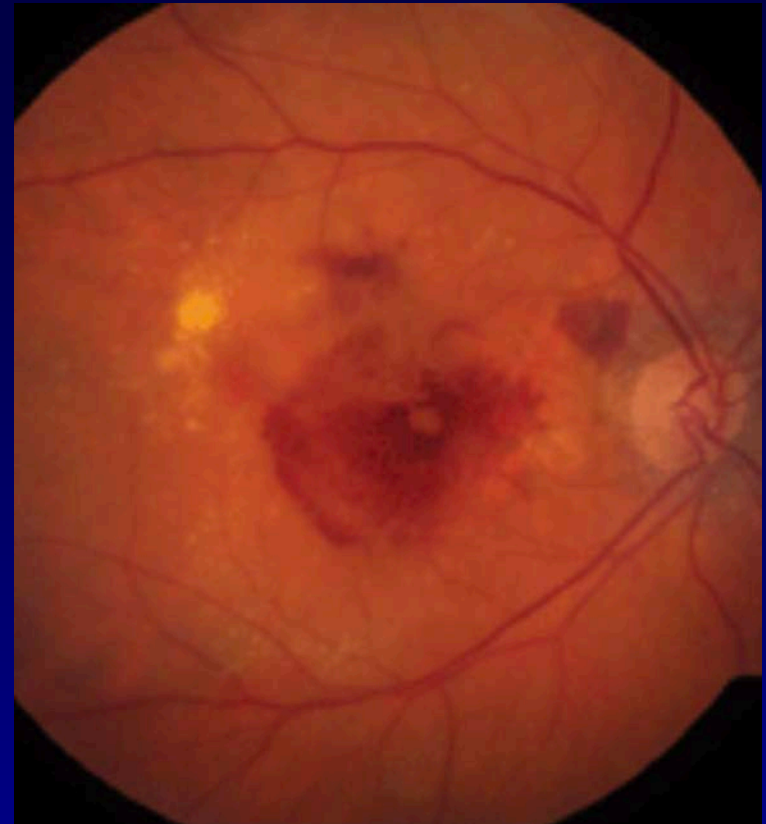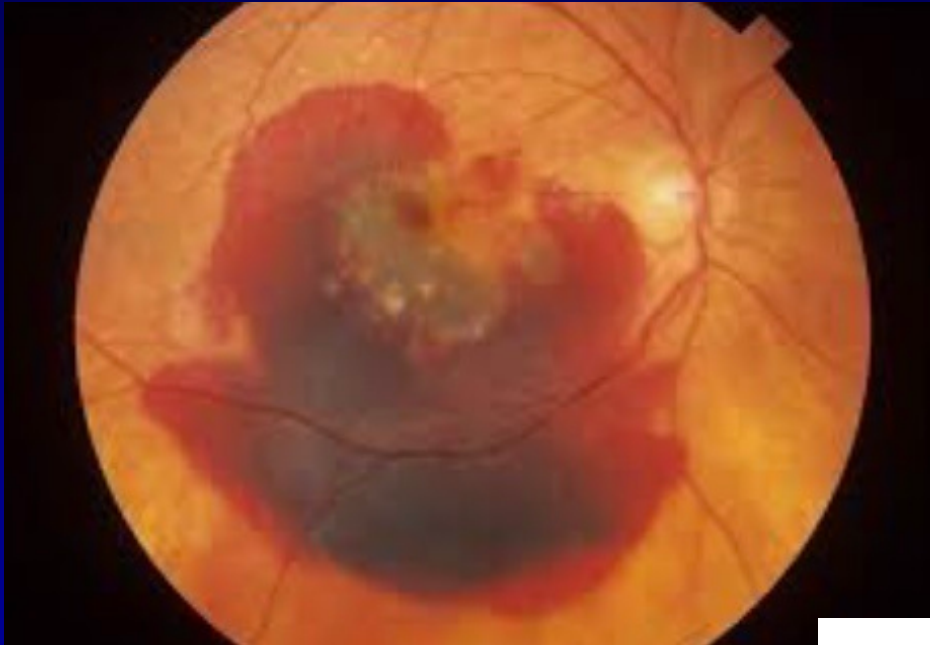67 years woman sudden
Unilateral

- Central scotoma
- Image distortion



Diagnosis?

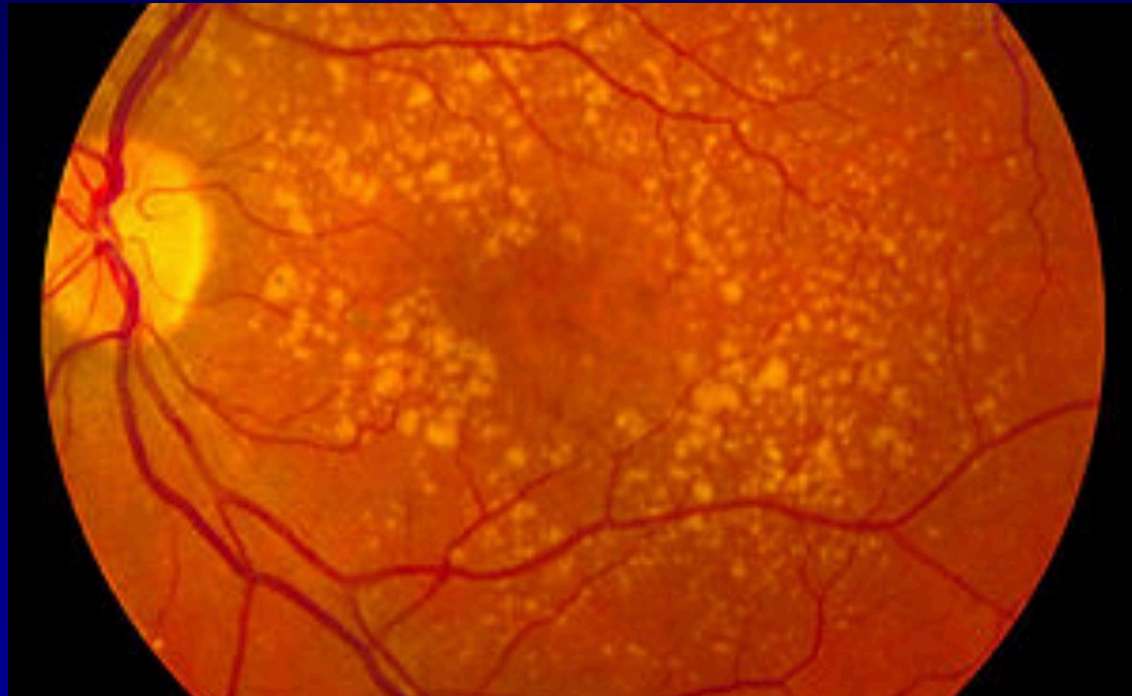
How urgent?



Name 2 other conditions that can cause similar symptoms?

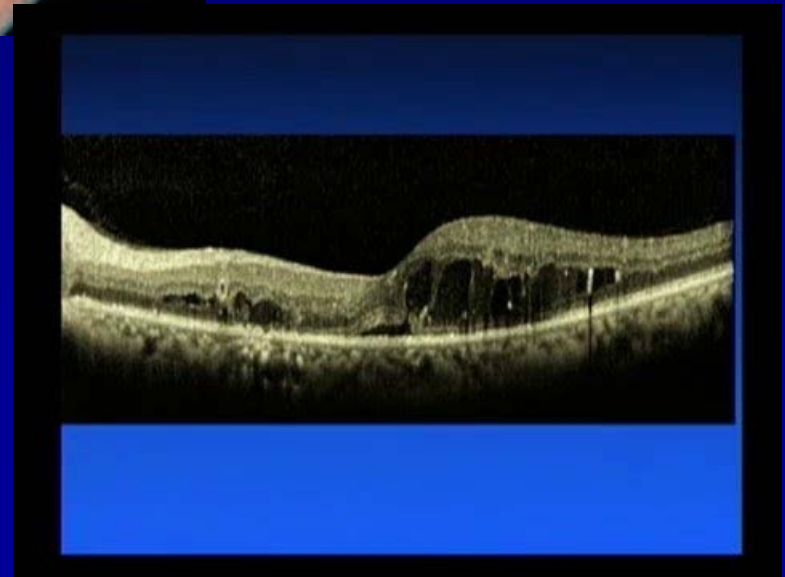
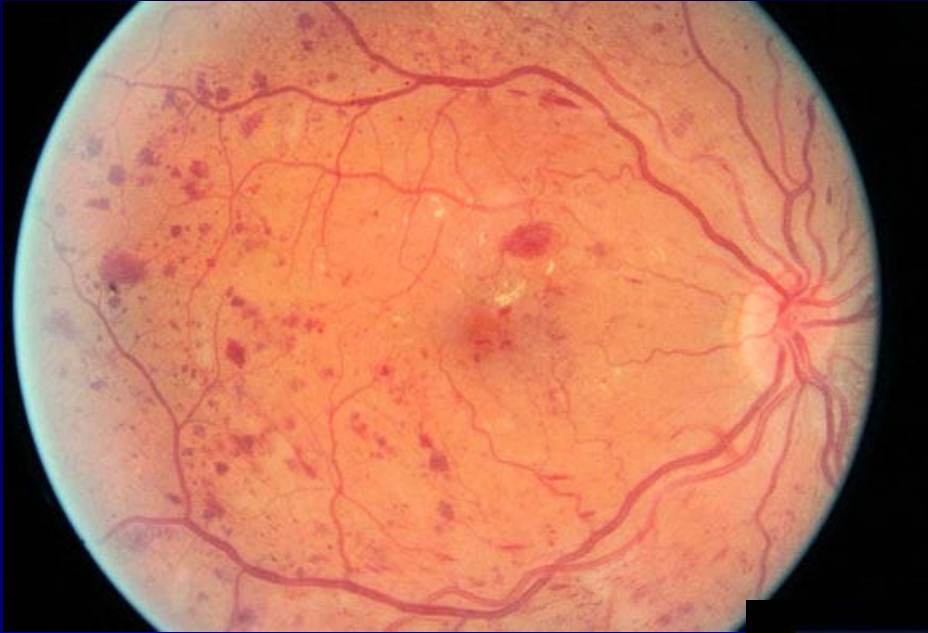Any treatment that you have known?

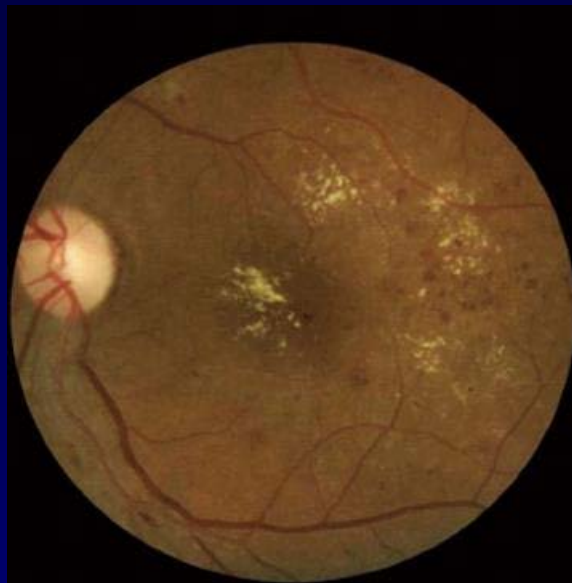What is the one & only risk factor apart from age?



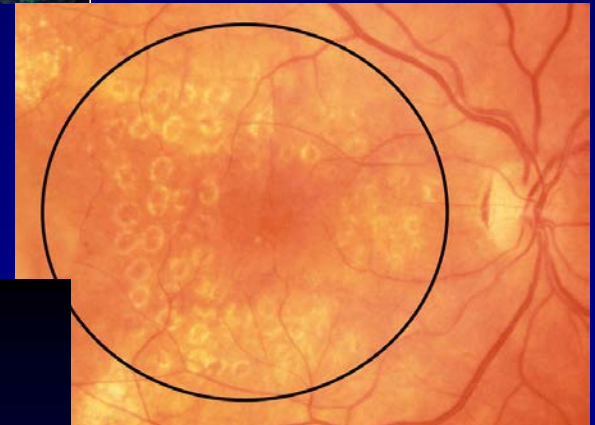

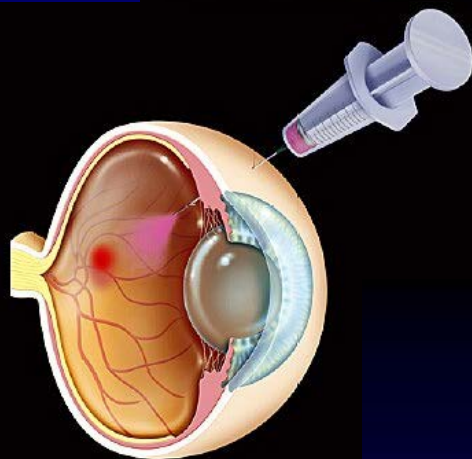
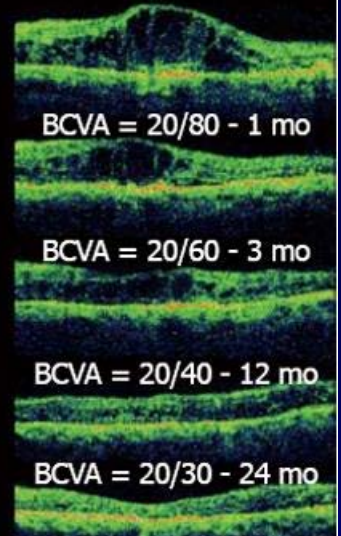
- Two differentials of central scotoma
- Dry AMD
- Diabetic maculopathy



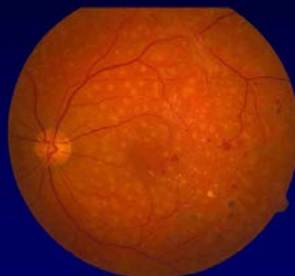




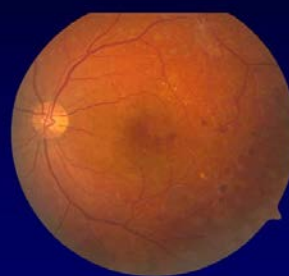
BCVA = 20/100 - baseline



Mild Macular Grid



40 minutes post laser
treatment



6 weeks post laser
treatment

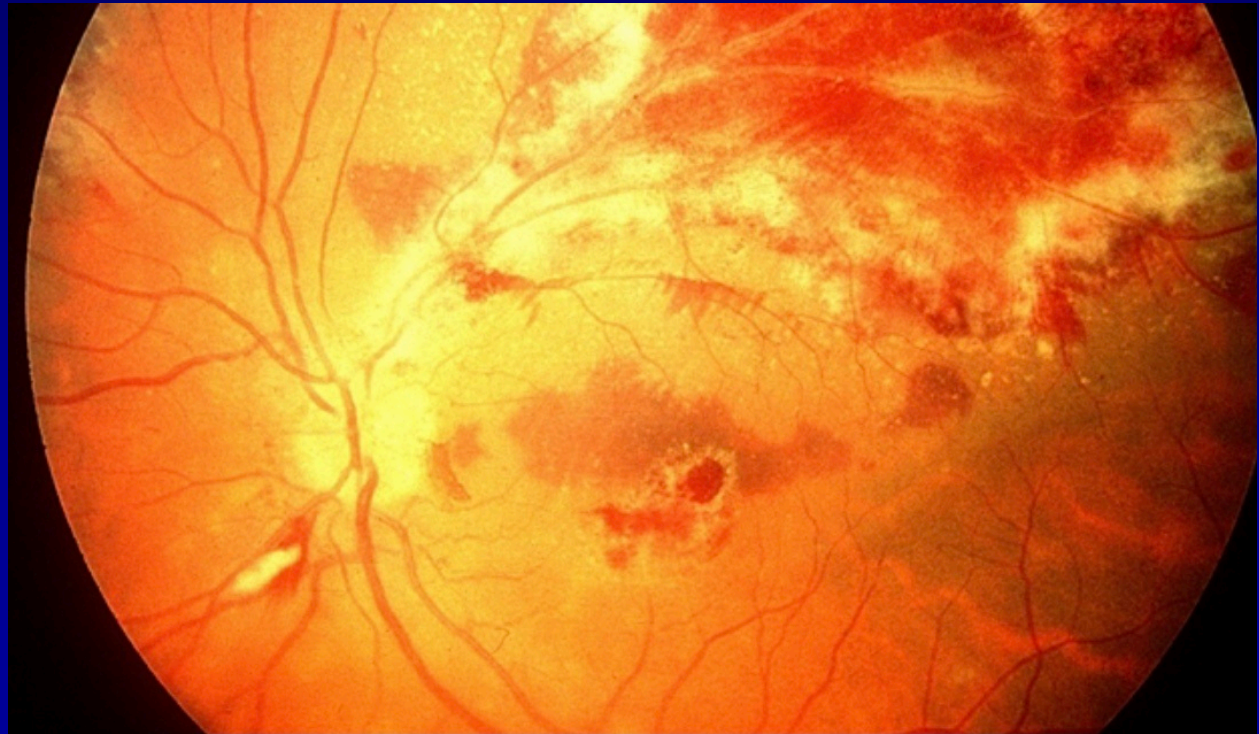
40 years old man referred from GU clinic for seeing
of shadow with one eye

Finding?

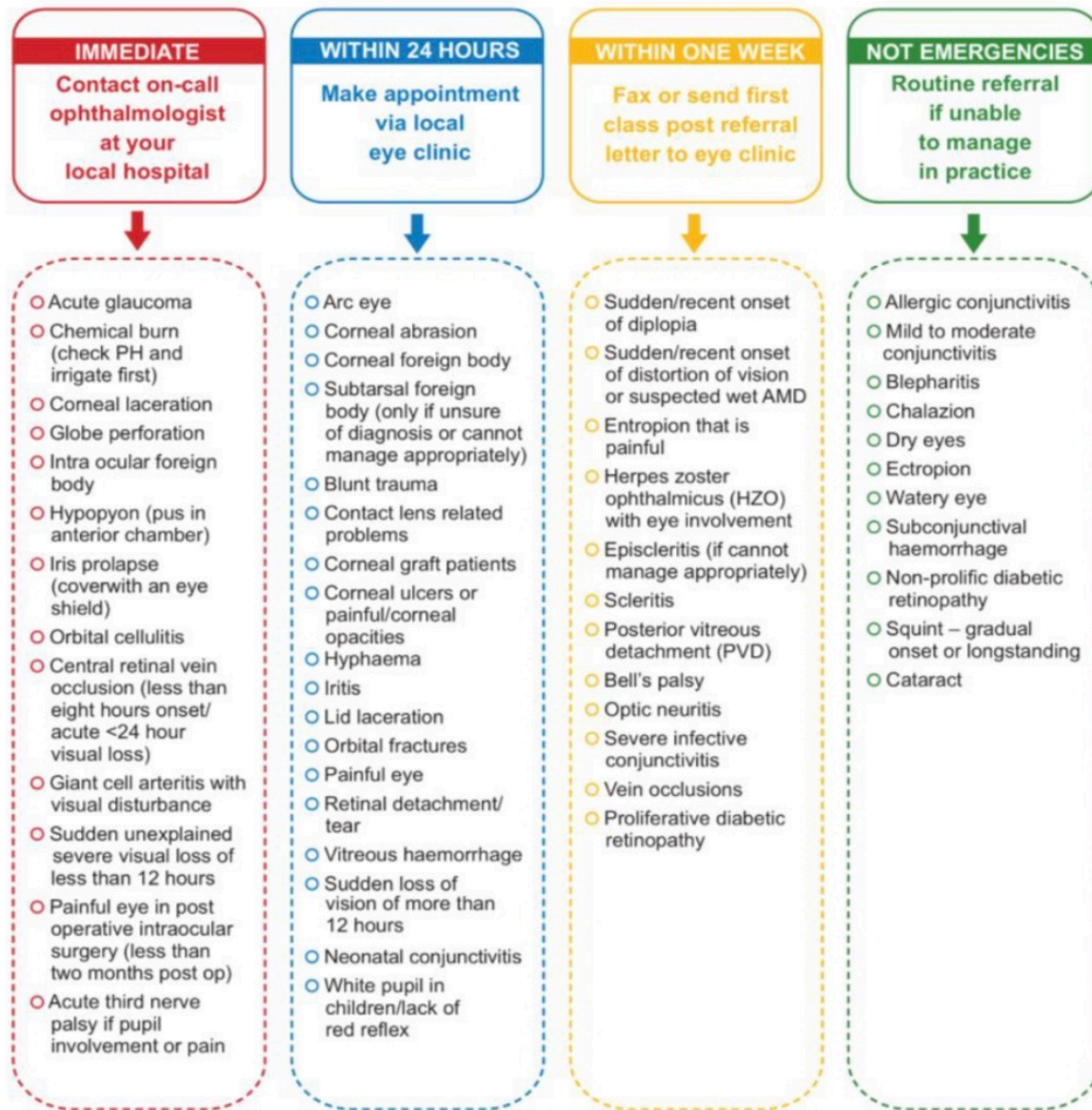
Medical history?

Any marker to have this condition?

Treatment?



When to refer to the ophthalmic department



Name 4 screenings that you know of & why important?

Screenings

Newborn

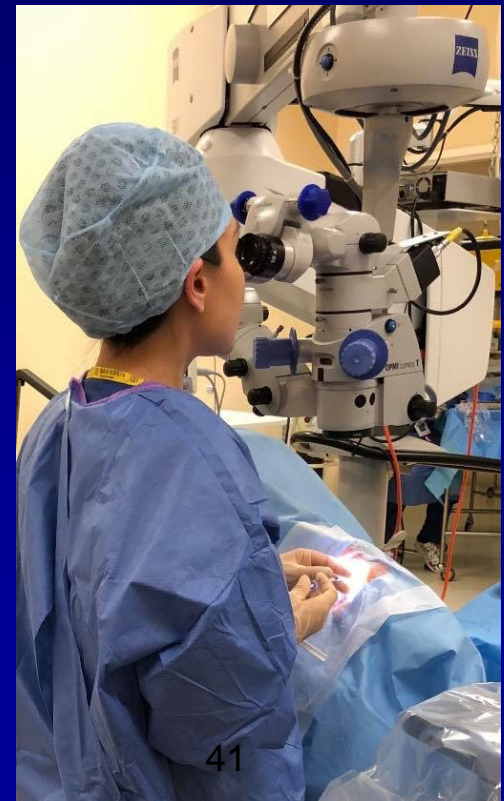
ROP screening

Preschool

JIA

Diabetic retinopathy

After 40 years of age, check with the optician for IOP. To prevent OAG.



IF UNSURE
REFER

Happy to take questions

Thank You



Mya.Ohn@southend.nhs.uk